



INTRODUCTION

- A spontaneous cerebrospinal fluid (CSF) leak occurs when the CSF egresses from the subarachnoid space of the anterior or middle cranial fossa into the surrounding sinonasal or middle ear cavities through a dehiscence of the lamina dura .
- The incidence has been estimated to be 5 per 100,000 per year, typically affecting women more than men (9:1) with a peak age of around 40 years .
- Neuro-ophthalmic biomarkers have not been studied in patients with CSF leaks, especially for its association with idiopathic intracranial hypertension prior to their spontaneous leak.

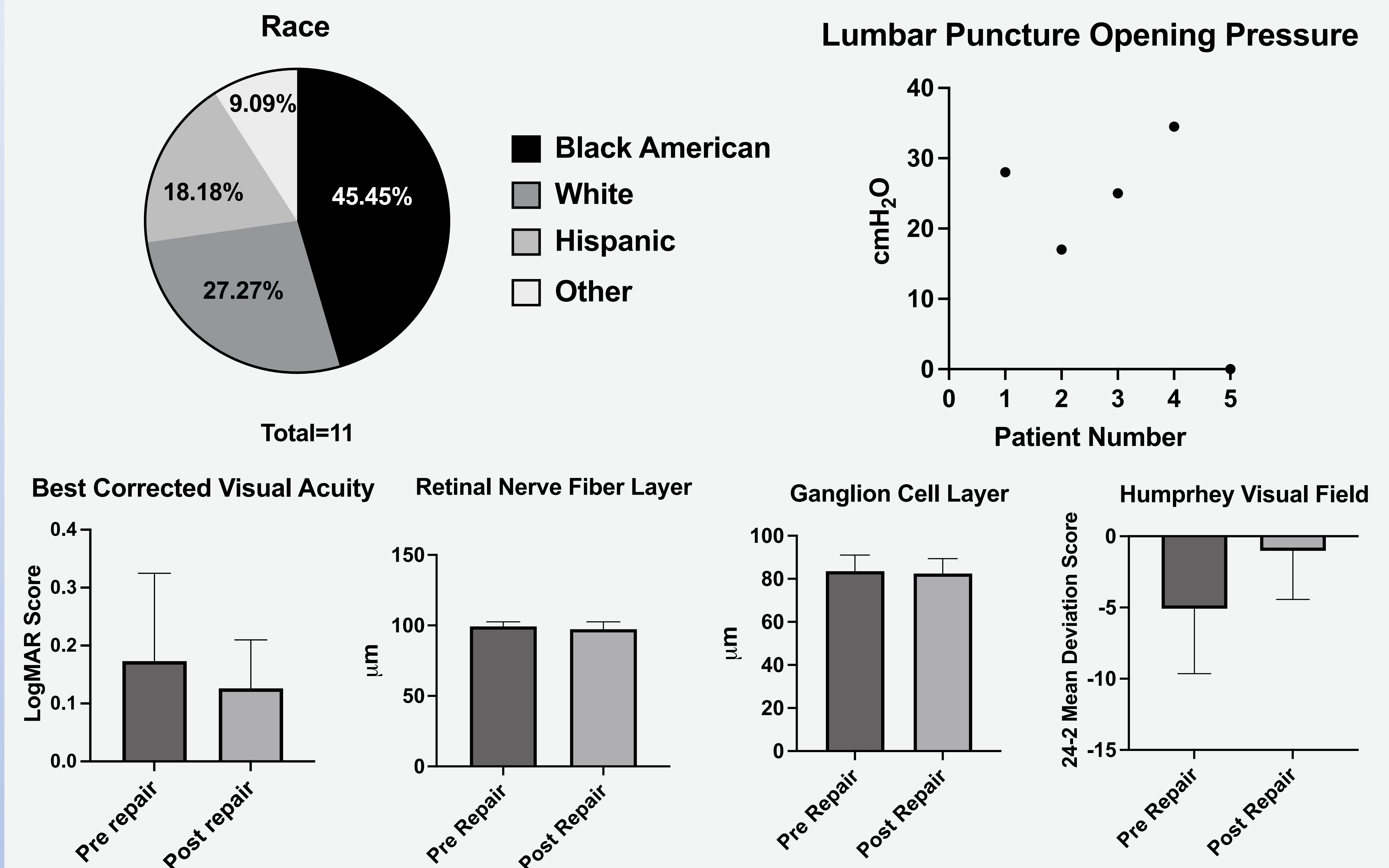
OBJECTIVES

- This study investigated the neuro-ophthalmic features of IIH in patients with sCSF leak.
- To further understand the association between these features and sCSF leak

METHODS

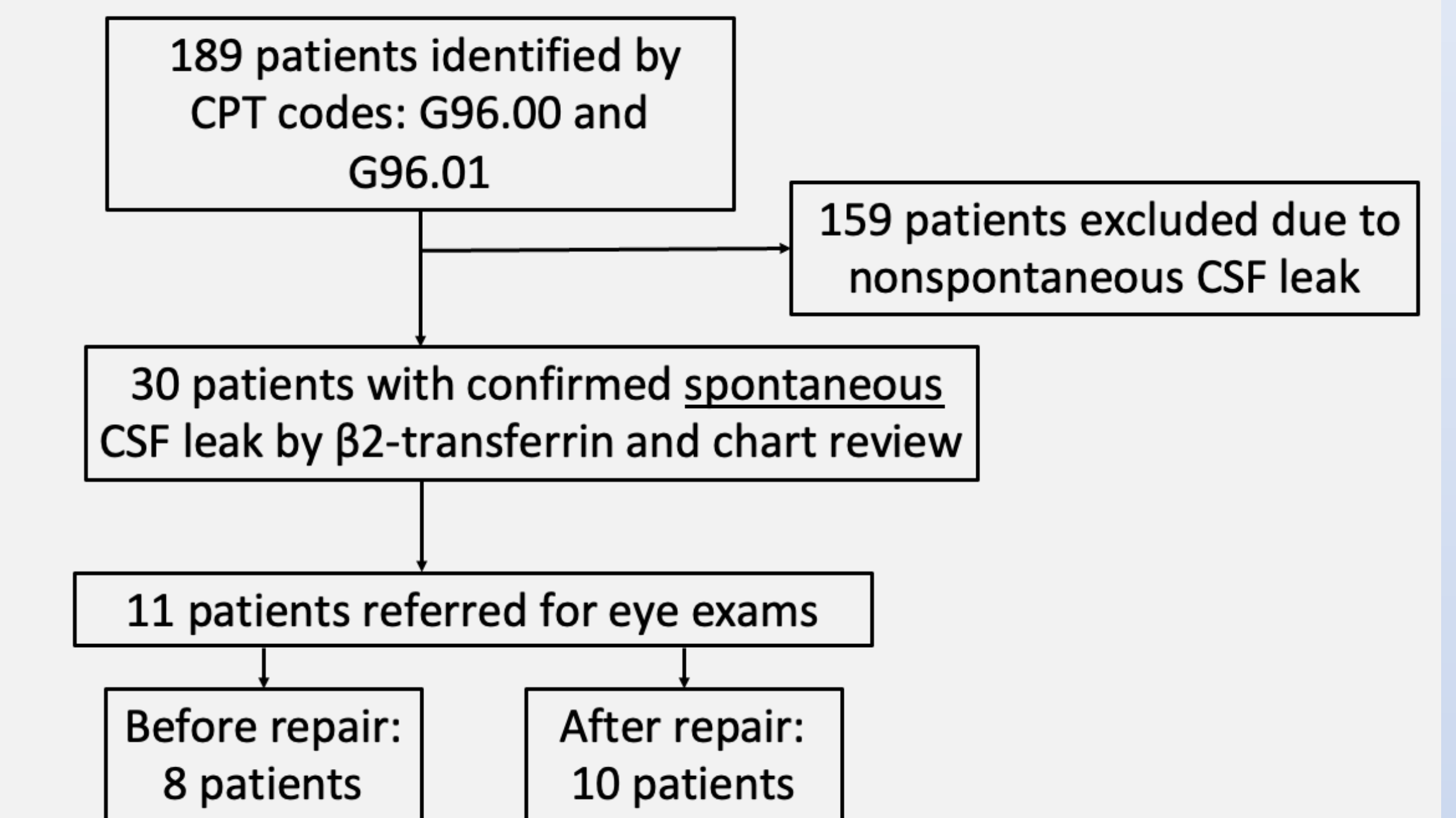
- A single institution, retrospective cohort study was conducted by querying for the CSF leak CPT codes (G96.00 and G96.01) in the electronic medical record system from June 2019 to July 2022.
- For patients with clinically confirmed diagnosis of sCSF leak, the demographics, eye exam and ophthalmic imaging details of both eyes were obtained.

RESULTS



- The mean age at sCSF diagnosis was 40.84 ± 10.26 and BMI was reported at 37.93 ± 7.41 .
- The best-corrected visual acuity was 20/30 prior to CSF leak repair and 20/25 post CSF leak repair ($p=0.398$).
- The intraocular pressure was 16 mm Hg prior to CSF leak repair and 16.21 post CSF leak repair ($p=0.819$).
- The mean retinal nerve fiber layer was $99.34\mu\text{m}$ prior to CSF leak repair and $97.35\mu\text{m}$ post CSF leak repair ($p=0.355$).
- The ganglion cell layer was $83.57\mu\text{m}$ prior to CSF leak repair and $82.47\mu\text{m}$ ($p=0.753$).
- The 24-2 mean deviation score for Humphrey Visual Field was -5.08 prior to CSF leak repair and -1.03 post CSF leak repair ($p=0.07$, normal values -2.00 to $+2.00$).

METHODS



CONCLUSION

- Given the similarities in demographics in patients with IIH and sCSF leak, neuro-ophthalmologic exams are recommended for all patients with sCSF leaks to screen for papilledema.
- A larger study is warranted to further investigate the association between IIH and recurrent sCSF leak through neuro-ophthalmologic exams.
- Future directions involve re-defining the multidisciplinary clinical management for sCSF leak, understanding the clinical use of acetazolamide post-operatively, and sleep apnea management to prevent recurrent leakage.

ACKNOWLEDGEMENTS

Special thanks to Dr. Shahlaie, Dr. Steele, Dr. Strong, and Dr. Liu for their continued mentorship and guidance on this research study.